

December 2023

“What should I do about this new Left Bundle Branch Block?”

Muhammad Asad Hanif

Department of Cardiology, Reading Hospital – Tower Health, West Reading, PA

Muhammad Mohsin Zafar

Department of Cardiology, Reading Hospital – Tower Health, West Reading, PA

Aniruddha Singh

Department of Cardiology, Reading Hospital – Tower Health, West Reading, PA

Follow this and additional works at: <https://scholarcommons.towerhealth.org/t-med>



Part of the [Medicine and Health Sciences Commons](#)

Recommended Citation

Hanif M, Zafar M, Singh A. “What should I do about this new Left Bundle Branch Block?”. *Transformative Medicine (T-Med)*. 2023; 2(4):105-107. doi: <https://doi.org/10.54299/tmed/kpri8559>.

This article is brought to you for free and open access by Tower Health. It has been accepted by an authorized editor for inclusion in Transformative Medicine (T-Med).

“What Should I Do About This New Left Bundle Branch Block?”

Muhammad Asad Hanif¹,
Muhammad Mohsin Zafar¹,
Aniruddha Singh¹

1. Department of Cardiology, Reading Hospital – Tower Health, West Reading, PA

Case Presentation
EKG Interpretation
Discussion
Clinical Course
Take Home Points
References

Published December 2023

CASE PRESENTATIONS:

We present two patient referrals to cardiology from a primary care physician’s (PCP) office for abnormal EKG.

Patient 1:

A 62-year-old male with past medical history of hypertension, hyperlipidemia, type 2 diabetes mellitus and obesity was evaluated at his PCP’s office for new onset dyspnea on exertion. Review of systems, vitals, and physical examination were unremarkable. An EKG was obtained with findings identical to those highlighted in Figure 1.

Patient 2:

An 84-year-old female with past medical history of hypertension was seen for an annual physical exam at his PCP’s office. The patient reported no concerns and stated that she was doing well. The physical exam was unremarkable, but vitals were significant for a blood pressure of 155/90 mmHg. An EKG was obtained with findings identical to those highlighted in Figure 1.

Questions:

1. How to diagnose LBBB on an EKG?
2. What is the best next step?

Correspondence to Muhammad Asad Hanif at muhammadasad.hanif@towerhealth.org

Disclosure Statement: The authors have no conflicts of interest to declare.

EKG INTERPRETATION

Left bundle branch block (LBBB), a pattern seen on surface EKG, results when normal electrical activity in the His-Purkinje system is interrupted. The diagnostic criteria is listed in Table 1.

Table 1. Diagnostic Criteria for LBBB. Reference: Surawicz B, Childers R, Deal BJ, et al. AHA/ACC/HRS Recommendations for the standardization and interpretation of the electrocardiogram. Part III. Intraventricular conduction disturbances. *J Am Coll Cardiol.* 53:976-981

Complete Left Bundle Branch Block

QRS duration \geq 120 msec

Broad, notched, or slurred R waves in leads I, aVL, V5 and V6

Small or absent initial r waves in leads V1 and V2 followed by deep S waves

Absent septal q waves in leads I, V5, V6

Prolonged time to peak R wave (>60 msec) in V5 and V6

The EKG shows prolonged QRS duration, which is the hallmark of LBBB and is typically greater than 120 milliseconds, due to the altered sequence of ventricular activation. There is a broad, slurred and notched R wave in aVL (blue oval). There is a small initial r wave in lead V1 and V2 followed by deep S wave (red oval). There are absent q waves in leads I, V5 and V6 (green oval). Additionally, left axis deviation, poor R wave progression and ST-T wave changes can occur, such as discordant ST-segment and T-wave changes opposite to the QRS complex (red oval).

Figure 1. 12-lead electrocardiogram

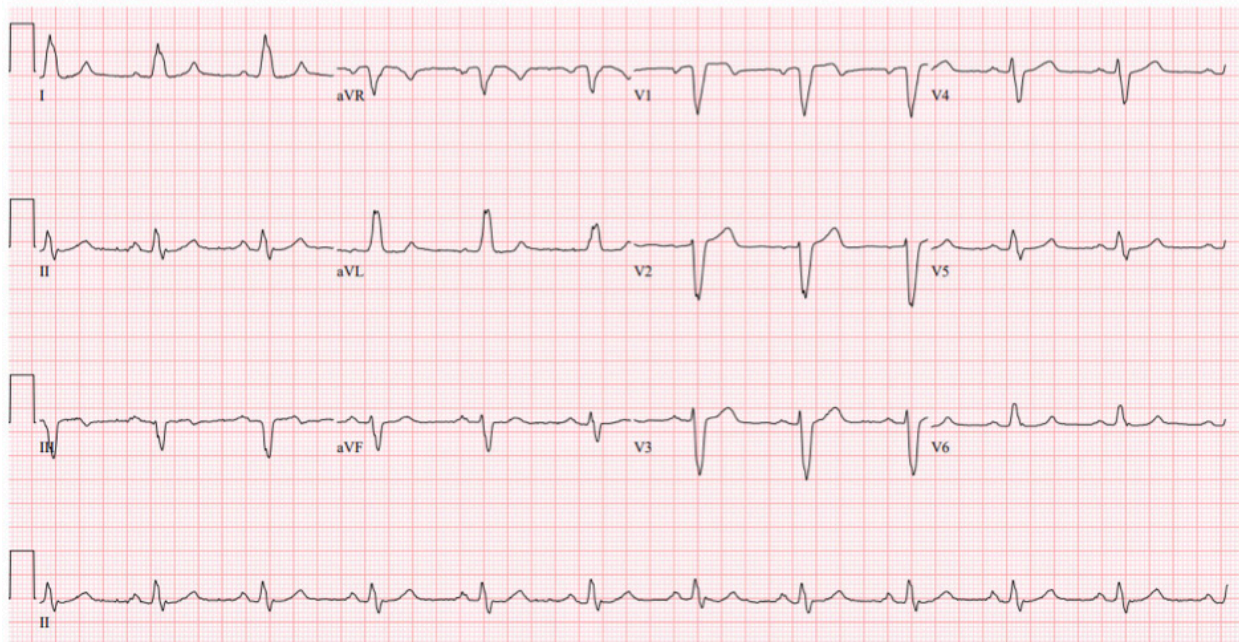
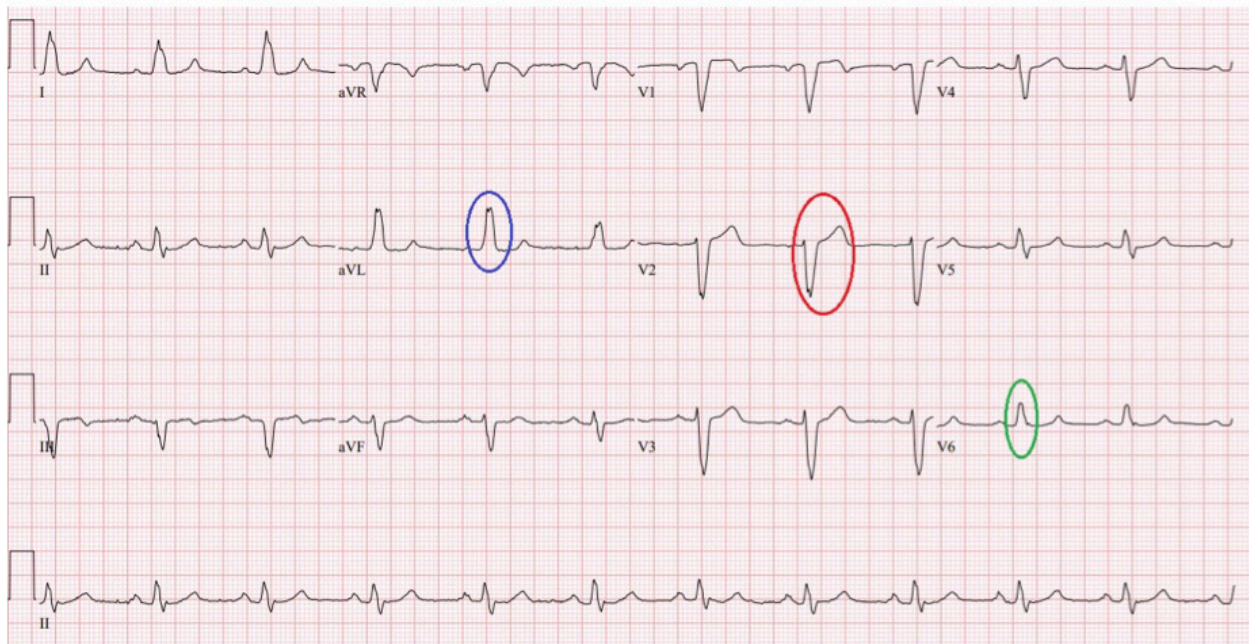


Figure 2. Annotated 12-lead electrocardiogram



DISCUSSION

LBBB is uncommon in the general population and has been estimated to have a prevalence of 0.2 to 1.1 percent [1-6]. Prevalence increases with age [7]. Studies have shown an association of LBBB with subsequent development of cardiovascular disease even in otherwise asymptomatic patients [8-9].

Younger patients with LBBB have a lower incidence of cardiovascular disease [7,10]. Structural heart disease is the etiology of LBBB in vast majority of cases. This most commonly involves myocardial fibrosis from one, or a combination of, numerous chronic conditions (e.g. hypertension, coronary artery disease (CAD), cardiomyopathies). LBBB can also result from acute myocardial insults

such as myocardial ischemia, myocardial infarction, endocarditis with abscess formation, or myocarditis, and in such circumstances is usually associated with a worse prognosis. LBBB may also develop following certain cardiac surgeries such as septal myectomy and transcatheter aortic valve implantation.

Hence, the best next step for a patient presenting to the office with a new LBBB is to obtain a thorough history and physical examination to evaluate for the above-mentioned etiologies as this will determine the need for, and the specifics of, further workup. It is also important to be cognizant of the fact that the EKG changes of LBBB obscure or simulate other EKG patterns and can complicate the diagnosis of conditions such as left ventricular hypertrophy (LVH), myocardial ischemia and infarction. The diagnosis of LVH can only be established by echocardiography in the setting of LBBB as both disorders produce similar EKG changes. If ischemia is a concern based on history, then stress testing should be pursued. Exercise EKG stress is inadequate due to the baseline EKG abnormalities associated with LBBB. Exercise radionuclide myocardial perfusion imaging (rMPI) should also be avoided due to high false positive rate. Vasodilator rMPI and stress echocardiography have higher diagnostic accuracy and either one can be chosen based upon available local expertise.

CLINICAL COURSE

Patient 1 was referred to cardiology and underwent an echocardiogram that was unremarkable. Given new onset dyspnea on exertion that could be an anginal equivalent, the patient also underwent stress testing with a vasodilator rMPI that was significant for ischemia in the left anterior descending (LAD) artery territory. Patient subsequently underwent a left heart catheterization that revealed a 90% proximal LAD stenosis that was stented and resulted in resolution of his symptoms. Patient was also initiated on aspirin, clopidogrel and high intensity statin for CAD.

Patient 2 was also referred to cardiology and underwent an echocardiogram to evaluate for structural heart disease. The echocardiogram revealed normal systolic function with moderate concentric LVH and was otherwise unremarkable. Changes of LVH were attributed to the patient’s longstanding history of uncontrolled hypertension and her antihypertensive regimen was intensified.

TAKE-HOME POINTS

- New LBBB should be evaluated with a focused history and physical examination to determine etiology and guide further workup

- EKG changes of LVH, myocardial ischemia and infarction are masked by LBBB
- If stress test is indicated based on history, then either vasodilator rMPI or stress echocardiography can be utilized
- Asymptomatic patients with new LBBB warrant an echocardiogram to evaluate for structural heart disease

REFERENCES

1. Siegman-Igra Y, Yahini JH, Goldbourt U, Neufeld HN. Intraventricular conduction disturbances: a review of prevalence, etiology, and progression for ten years within a stable population of Israeli adult males. *Am Heart J.* 1978 Nov;96(5):669-79. [https://doi.org/10.1016/0002-8703\(78\)90205-3](https://doi.org/10.1016/0002-8703(78)90205-3). PMID: 400746.
2. Ostrander LD Jr, Brandt RL, Kjelsberg MO, Epstein FH. Electrocardiographic Findings Among the Adult Population of a Total Natural Community, Tecumseh, Michigan. *Circulation.* 1965 Jun;31:888-98. <https://doi.org/10.1161/01.CIR.31.6.888>. PMID: 14297523.
3. Hiss RG, Lamb LE. Electrocardiographic findings in 122,043 individuals. *Circulation.* 1962 Jun;25:947-61. <https://doi.org/10.1161/01.CIR.25.6.947>. PMID: 13907778.
4. Zhang ZM, Rautaharju PM, Soliman EZ, Manson JE, Cain ME, Martin LW, Bavry AA, Mehta L, Vitols M, Prineas RJ. Mortality risk associated with bundle branch blocks and related repolarization abnormalities (from the Women’s Health Initiative [WHI]). *Am J Cardiol.* 2012 Nov 15;110(10):1489-95. <https://doi.org/10.1016/j.amjcard.2012.06.060>. Epub 2012 Aug 2. PMID: 22858187.
5. Badheka AO, Singh V, Patel NJ, Deshmukh A, Shah N, Chothani A, Mehta K, Grover P, Savani GT, Gupta S, Rathod A, Marzouka GR, Mitrani RD, Moscucci M, Cohen MG. QRS duration on electrocardiography and cardiovascular mortality (from the National Health and Nutrition Examination Survey-III). *Am J Cardiol.* 2013 Sep 1;112(5):671-7. <https://doi.org/10.1016/j.amjcard.2013.04.040>. Epub 2013 May 29. PMID: 23726176.
6. Tan NY, Witt CM, Oh JK, Cha YM. Left Bundle Branch Block: Current and Future Perspectives. *Circ Arrhythm Electrophysiol.* 2020 Apr;13(4):e008239. <https://doi.org/10.1161/CIRCEP.119.008239> Epub 2020 Mar 18. PMID: 32186936.
7. Eriksson P, Hansson PO, Eriksson H, Dellborg M. Bundle-branch block in a general male population: the study of men born 1913. *Circulation.* 1998 Dec 1;98(22):2494-500. <https://doi.org/10.1161/01.CIR.98.22.2494>. PMID: 9832497.
8. Schneider JF, Thomas HE Jr, Kreger BE, McNamara PM, Kannel WB. Newly acquired left bundle-branch block: the Framingham study. *Ann Intern Med.* 1979 Mar;90(3):303-10. <https://doi.org/10.7326/0003-4819-90-3-303>. PMID: 154870.
9. Fahy GJ, Pinski SL, Miller DP, McCabe N, Pye C, Walsh MJ, Robinson K. Natural history of isolated bundle branch block. *Am J Cardiol.* 1996 Jun 1;77(14):1185-90. [https://doi.org/10.1016/S0002-9149\(96\)00160-9](https://doi.org/10.1016/S0002-9149(96)00160-9). PMID: 8651093.
10. Rotman M, Triebwasser JH. A clinical and follow-up study of right and left bundle branch block. *Circulation.* 1975 Mar;51(3):477-84. <https://doi.org/10.1161/01.CIR.51.3.477>. PMID: 1132086.