

Tower Health

Scholar Commons @ Tower Health

Reading Hospital Internal Medicine Residency

Internal Medicine Residency

2-6-2018

Primary thyroid MALToma- a rare diagnosis of an unassuming thyroid nodule.

Pragya Shrestha

Department of Internal Medicine, Reading Health System, West Reading, PA,
pragya.shrestha@towerhealth.org

Kimberly Aderhold

Department of Hematology and Medical Oncology, Thomas Jefferson University Hospital, Philadelphia, PA

Sharon Swierczynski

Department of Pathology, Reading Health System, PA, sharon.swierczynski@towerhealth.org

Catherine Lin

Department of Internal Medicine, Reading Health System, West Reading, PA

Ronald Herb

Department of Internal Medicine, Reading Health System, West Reading, PA, ronald.herb@towerhealth.org

Follow this and additional works at: <https://scholarcommons.towerhealth.org/>

[gme_int_med_resident_program_read](#)



Part of the [Internal Medicine Commons](#)

Recommended Citation

Shrestha, P., Aderhold, K., Swierczynski, S., Lin, C., & Herb, R. (2018). Primary thyroid MALToma- a rare diagnosis of an unassuming thyroid nodule.. *J Community Hosp Intern Med Perspect*, 8 (1), 42-45.
<https://doi.org/10.1080/20009666.2018.1424487>

This Article is brought to you for free and open access by the Internal Medicine Residency at Scholar Commons @ Tower Health. It has been accepted for inclusion in Reading Hospital Internal Medicine Residency by an authorized administrator of Scholar Commons @ Tower Health. For more information, please contact alexandra.short@towerhealth.org.

CASE REPORT



Primary thyroid MALToma– a rare diagnosis of an unassuming thyroid nodule

Pragya Shrestha ^a, Kimberly Aderhold^b, Sharon Swierczynski^c, Catherine Lin^a and Ronald Herb^a

^aDepartment of Internal Medicine, Reading Health System, PA, USA; ^bDepartment of Hematology and Medical Oncology, Thomas Jefferson University Hospital, Philadelphia, PA, USA; ^cDepartment of Pathology, Reading Health System, PA, USA

ABSTRACT

Primary thyroid lymphoma, although a rare malignancy, can arise in common chronic inflammatory conditions such as Hashimoto's thyroiditis. Incidental finding of a thyroid nodule with chronic thyroid inflammation warrants further investigation. Early detection of malignancy can play a vital role in improved outcomes. We report a case of a 60-year-old male who presented to the clinic for a routine visit. An enlarged, firm, non-tender thyroid gland was appreciated on exam with high thyroid stimulating hormone (TSH) level. Fine needle aspiration of the mass revealed nonspecific atypical lymphocytes. The pathology and immunohistochemical stains were consistent with histologic impression of extra nodal marginal B-cell lymphoma (mucosa-associated lymphoid tissue [MALT] lymphoma) and Hashimoto's thyroiditis. Patient was treated with thyroxine after complete surgical excision of left thyroid lobe and remains in remission with close follow-up with his primary care provider. Primary thyroid MALT lymphoma follows an indolent process and remains asymptomatic in most patients. These are usually found to arise at sites of ongoing chronic inflammation with underlying autoimmune or infectious etiologies. Treatment modalities include surgical excision and/or radiation therapy for localized lesions, with both radiation and chemotherapy indicated for disseminated disease.

ARTICLE HISTORY

Received 17 November 2017
Accepted 28 December 2017

KEYWORDS

Thyroid lymphoma; thyroid MALToma; MALT lymphomas; thyroid nodule; lymphoma

1. Background

Mucosa-associated lymphoid tissue (MALT) lymphoma is defined as extra nodal lymphoma composed of heterogeneous small B cells arising from marginal zone of MALT [1]. It most frequently occurs in the gastrointestinal tract mucosa (50%), head and neck (15%), lung (14%), skin (11%), thyroid (4%), and breast (4%) [1–3]. Primary thyroid lymphoma (PTL) is a rare form of malignancy, constituting about 2–8% of all thyroid malignancies and 1–2% of all extra nodal lymphomas [3,4]. Thyroid lymphomas are most commonly diffuse large B-cell lymphomas (60–80%), and only about 30% are extra nodal marginal zone lymphomas [3]. Primary thyroid MALT lymphoma is rare, accounting 6–28% of PTLs [5] and usually arises in the setting of chronic lymphocytic thyroiditis, such as Hashimoto's thyroiditis [2]. The mean and median ages at diagnosis is between 65 and 75 years with 4:1 female predominance [5–7]. Co-occurrence of papillary thyroid carcinoma has also been reported [3,8]. Diagnosis requires a high degree of suspicion and is often difficult due to coexistence of reactive as well as neoplastic processes in the thyroid gland.

2. Case description

A 60-year-old male presented to our outpatient clinic for a routine visit. He had no complaints except for

minimal hand dryness and denied fatigue, generalized weakness, heat or cold intolerance, constipation, diarrhea, hair loss, or any recent weight changes. His past medical history was pertinent for a basal cell carcinoma of scalp treated with extensive excision 3 years prior.

On physical examination, an enlarged, firm, non-tender thyroid gland was appreciated with about 3 cm left thyroid lobe mass felt on palpation. Xerosis of hands, arms, and legs were also noted with no pruritus or erythematous rash. No palpable lymphadenopathies or hepatosplenomegaly was noted. He denied any lump like sensation in his neck, neck pain, difficulty in swallowing, hoarseness, or dry cough. Signs of tracheal, esophageal, or neck vein compression were not found. He was an active smoker (35 pack-years) but did not have any history of radiation exposure, family history of thyroid-related disorders, or malignancy. His diet was normal with iodine-rich meals.

Complete blood count and basic metabolic profile were within normal limits. TSH was found to be elevated at 10.14 uIU/mL. All other lab values were within normal limit. Thyroid ultrasound was done which revealed large 5.8 × 3.1 × 2.5 cm hypoechoic mass occupying almost complete volume of the left thyroid lobe, and persistent elevation of TSH was found in repeat thyroid panel. Patient underwent

CONTACT Pragya Shrestha  pragya.shrestha@towerhealth.org  Department of Internal Medicine, Reading Health System, 6th Avenue and Spruce Street, West Reading, PA 19611, USA

© 2018 The Author(s). Published by Informa UK Limited, trading as Taylor & Francis Group.
This is an Open Access article distributed under the terms of the Creative Commons Attribution-NonCommercial License (<http://creativecommons.org/licenses/by-nc/4.0/>), which permits unrestricted non-commercial use, distribution, and reproduction in any medium, provided the original work is properly cited.

fine needle aspiration (FNA) of the mass which revealed ‘indeterminate follicular neoplasm’ (Bethesda category IV). The cytologic features were suspicious for neoplastic process, and differential diagnosis was broad including medullary thyroid carcinoma, neuroendocrine tumors, hematolymphoid process, as well as metastatic malignancy.

With concern for malignancy, Positron Emission Tomography – Computed Tomography (PET – CT) scan was done. This revealed intensely hypermetabolic left thyroid mass and mildly hypermetabolic and prominent juxta thyroid lymph nodes in the left neck. Diffuse uptake throughout the remainder of the thyroid gland was present – a common finding associated with Hashimoto’s thyroiditis. Considering probable malignancy which was thus far undefined, decision for thyroid lobectomy was made.

The pathology and immunohistochemical (IHC) stains of the excised left thyroid lobe supported histologic impression of extra nodal marginal B-cell lymphoma (MALT lymphoma) with Hashimoto’s thyroiditis. IHC indicated positivity for CD20, CD79A, CD43, and CD45. IHC of Superior level 6 lymph node did not reveal any pathologic changes. Bone marrow was performed subsequently which did not show any evidence of infiltrating lymphoma.

Patient was determined to be at stage IAE (Ann Arbor staging) considering his disease was limited to the thyroid gland without marrow infiltration, evidence of metastatic disease, or B symptoms. He was started on thyroxine replacement and then referred to Medical and Radiation Oncology, where further radiation therapy was recommended. He remains in a close follow-up with his primary care provider and continues to be in remission. He deferred further radiation therapy.

3. Discussion

Primary thyroid MALT lymphoma follows an indolent course and presents without any overt symptoms. Although most lymphomas present with typical ‘B’ symptoms such as fever, nocturnal sweating, and weight loss, this is usually not seen in this disease process, which make the diagnosis even more challenging [2,3]. Approximately 10% of patients may have these symptoms and 10% may have features of hypothyroidism, usually associated with Hashimoto’s thyroiditis [6].

MALT lymphomas are initially recognized at mucosal tissues, hence defined as tumors of mucosa-associated origin. Since first described by Isaacson and Wright [6], various extra nodal locations have been defined and studied. These were usually found to arise at the sites where ongoing chronic inflammation with underlying autoimmune or infectious etiologies was observed [2]. For

example, MALT lymphoma of the stomach has been associated with chronic infection with *Helicobacter pylori*. A similar pathophysiology is seen with chronic inflammation of thyroid gland in the setting of ongoing Hashimoto’s thyroiditis, as observed in our patient. Nevertheless, association of *H. pylori* and thyroid MALT lymphoma has not been adequately addressed in the literature [3]. Thyroid gland does not contain any native lymphoid tissue; in fact, lymphoid tissues can only be seen in pathological conditions, mostly involving autoimmune processes like Hashimoto’s thyroiditis [2]. Histologically, lymphocytic infiltration of stroma with oxyphilic change of follicular epithelium is seen in autoimmune thyroiditis, as opposed to atypical lymphoid cells originating within marginal zone of lymphoid follicles and extending into interfollicular spaces and germinal centers (follicular colonization) which is seen in MALT lymphoma [2,3,6]. In our patient, FNA showed neoplastic proliferation of mostly singly dispersed small- to medium-sized cells with lymphoid cell proliferation, composed predominantly of small mature lymphocytes. As can be seen in Figure 1, histologic sections of thyroid parenchyma showing architectural effacement by an atypical lymphoid infiltrate with a focally nodular pattern. Also, demonstrated in Figure 2 is a focus of intraluminal lymphoma cells, representing a so-called ‘MALT ball.’ IHC stain and phenotype of neoplastic cells of MALT lymphoma are regarded to be virtually identical to that of non-neoplastic marginal zone B cells which are positive for CD20, CD 22, and CD79A and negative for CD5 and CD10.

Treatment of thyroid MALT lymphoma depends upon its stage and subtype. Localized thyroid MALT lymphoma can be treated with surgical resection with 100% survival at 5 years [5,8–10]. Review of 103 cases done by Tsang et al. with localized (stage IE/IIIE) extra nodal MALT lymphoma had overall 5 years survival of 98% in 85 patients with extra nodal MALT lymphoma treated with radiation therapy alone [11]. The optimal treatment regimen and follow-up for these patients remains controversial. Five-year disease-specific survival has been found to be variable (35–79%) in literature due to differences in population size, study design, lymphoma classification, and treatment modalities used [6]. The stage and histologic grade do play a major role in determining prognosis of the disease process. Diffuse large B-cell lymphoma has a poorer prognosis compared to localized primary MALToma. Stages I/II respond well to localized treatment as compared to stages III/IV which are more disseminated and need combine modalities of chemo and radiation therapy [6,10]. Patients who present with enlarging tumors or symptoms of compression also have poorer

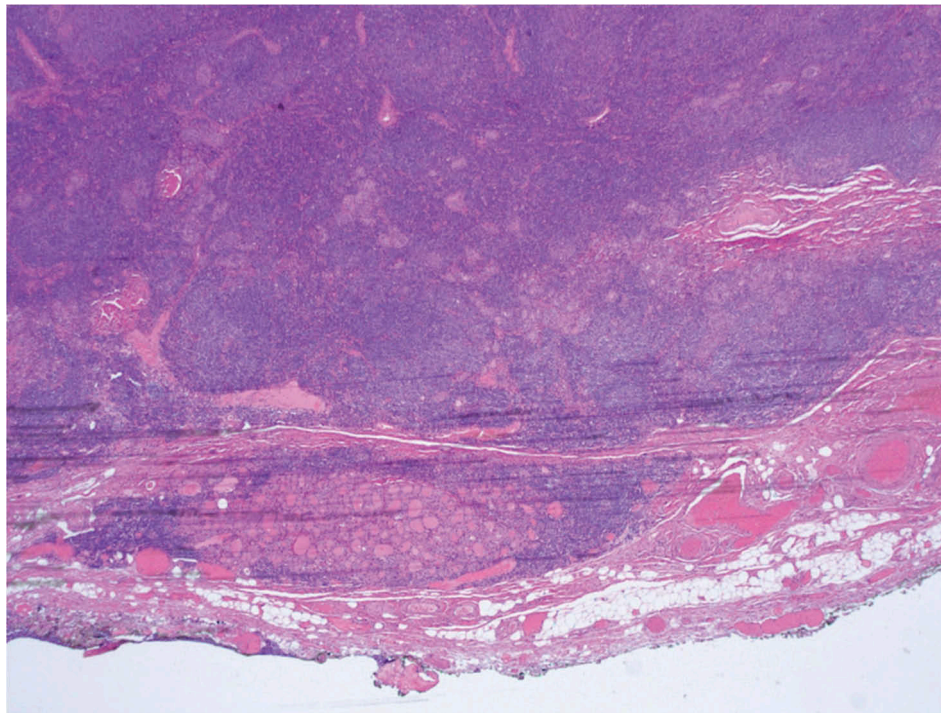


Figure 1. Histologic sections of thyroid parenchyma on low power demonstrate architectural effacement by an atypical lymphoid infiltrate with a focally nodular pattern.

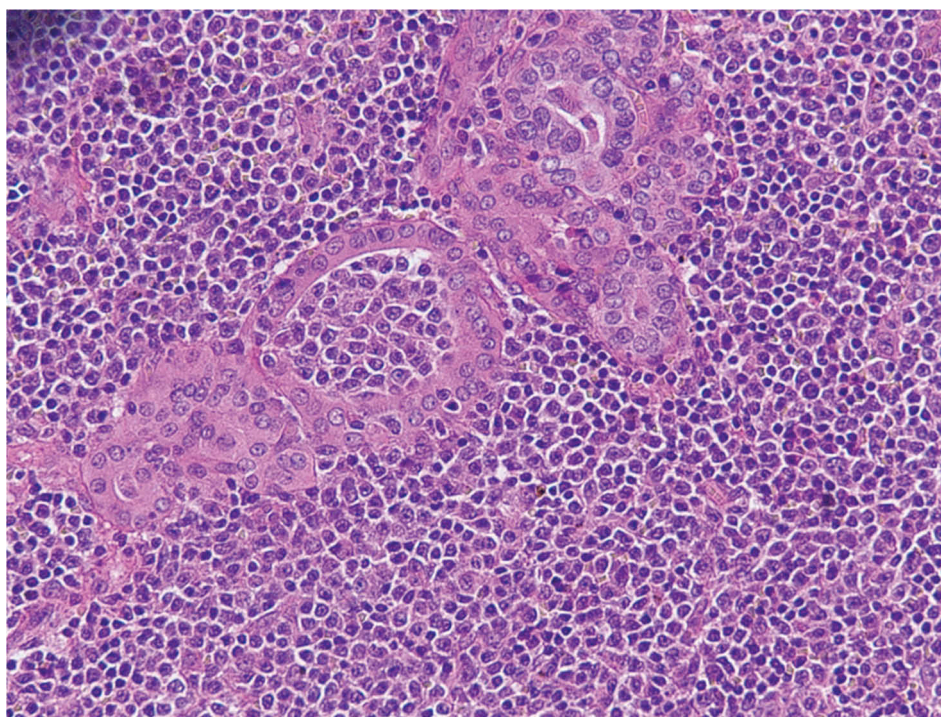


Figure 2. Histologic sections demonstrate intraepithelial lymphocytosis with involvement of the thyroid epithelium by the neoplastic lymphocytes. Shown is a focus of intraluminal lymphoma cells, representing a so-called 'MALT ball'.

prognosis [10]. Although this disease has excellent survival rate after treatment, the optimal follow-up remains controversial at present [5,10].

A usual practical approach is surgical excision for the localized disease, followed by radiotherapy and chemotherapy for disseminated disease [8]. However, some recent studies support radiation therapy as a

primary modality of treatment in patients at Stages IE and IIE and adjuvant therapy for those who are suspected to have some residual disease even after thyroidectomy procedure [3,12]. Unfortunately, due to rare occurrence of PTL and lack of larger randomized controlled studies, definitive guidelines for treatment and follow-up on these patient groups are awaited.

4. Conclusion

Primary thyroid MALT lymphoma follows an indolent process and remains asymptomatic in most patients with occasional nonspecific symptoms. It requires a high index of suspicion for diagnosis, and should be considered in patients with chronic inflammatory conditions of thyroid in presence of thyroid nodules. Treatment modalities include surgical excision and/or radiation therapy for localized lesions, with both radiation and chemotherapy indicated for disseminated disease.

Disclosure statement

No potential conflict of interest was reported by the authors.

Funding

None.

ORCID

Pragya Shrestha  <http://orcid.org/0000-0003-2864-1961>

References

- [1] Terada T. Extranodal marginal zone B-cell lymphoma of mucosa-associated lymphoid tissue (MALT lymphoma) in ulcerative colitis. *Saudi J Gastroenterol Off J Saudi Gastroenterol Assoc.* 2014;20(5):319–322.
- [2] Latheef N, Shenoy V, Kamath MP, et al. Maltoma of thyroid: a rare thyroid tumour. *Case Rep Otolaryngol.* 2013;2013:740241.
- [3] Peppas M, Nikolopoulos P, Korkolopoulou P, et al. Primary mucosa-associated lymphoid tissue thyroid lymphoma: a rare thyroid neoplasm of extrathyroid origin. *Rare Tumors.* 2012 Jan 2;4(1):4–6.
- [4] Stein SA. Primary thyroid lymphoma: a clinical review. *J Clin Endocrinol Metab.* 2013 Aug;98(8):3131–3138.
- [5] Derringer GA, Thompson LD, Frommelt RA, et al. Malignant lymphoma of the thyroid gland: a clinicopathologic study of 108 cases. *Am J Surg Pathol.* 2000 May;24(5):623–639.
- [6] Isaacson P, Wright DH. Malignant lymphoma of mucosa-associated lymphoid tissue. A distinctive type of B-cell lymphoma. *Cancer.* 1983 Oct 15;52(8):1410–1416.
- [7] Pedersen RK, Pedersen NT. Primary non-Hodgkin's lymphoma of the thyroid gland: a population based study. *Histopathology.* 1996;28(1):25–32.
- [8] Nam YJ, Kim BH, Lee SK, et al. Co-occurrence of papillary thyroid carcinoma and mucosa-associated lymphoid tissue lymphoma in a patient with long-standing Hashimoto thyroiditis. *Endocrinol Metab Seoul Korea.* 2013 Dec;28(4):341–345.
- [9] Thieblemont C, Mayer A, Dumontet C, et al. Primary thyroid lymphoma is a heterogeneous disease. *J Clin Endocrinol Metab.* 2002 Jan;87(1):105–111.
- [10] Mack LA, Pasiaka JL. An evidence-based approach to the treatment of thyroid lymphoma. *World J Surg.* 2007 May;31(5):978–986.
- [11] Tsang RW, Gospodarowicz MK, Pintilie M, et al. Localized mucosa-associated lymphoid tissue lymphoma treated with radiation therapy has excellent clinical outcome. *J Clin Oncol Off J Am Soc Clin Oncol.* 2003 Nov 15;21(22):4157–4164.
- [12] Friedberg MH, Coburn MC, Monchik JM. Role of surgery in stage IE non-Hodgkin's lymphoma of the thyroid. *Surgery.* 1994 Dec;116(6):1061–1066; discussion 1066–1067.